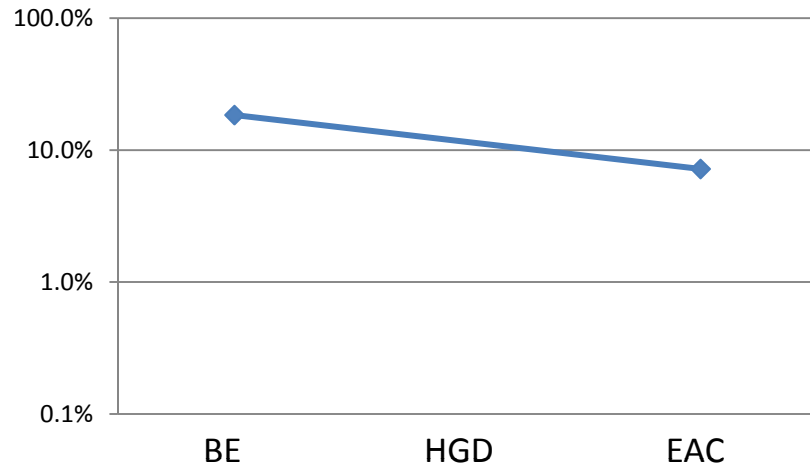
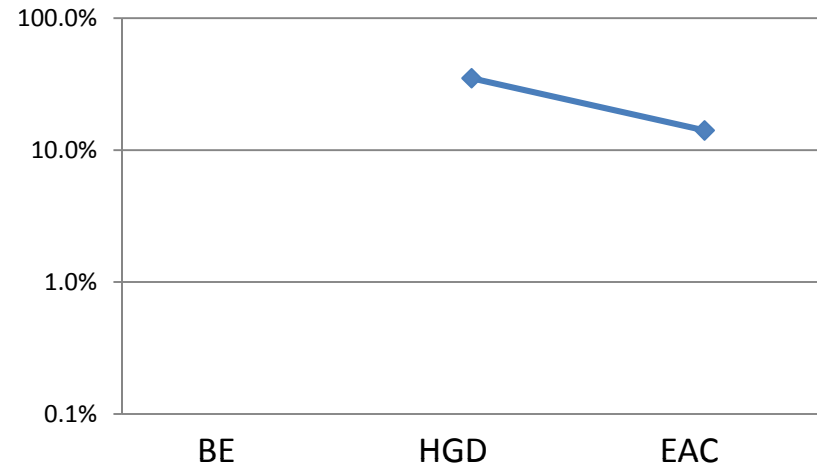


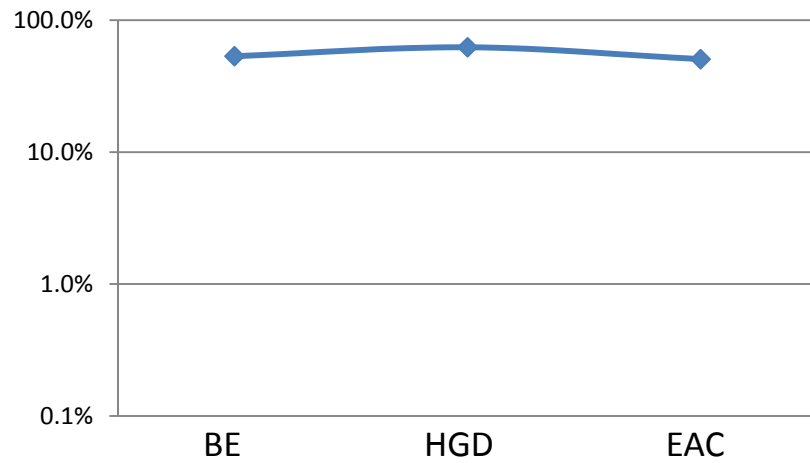
**Concurrent Patient 11**



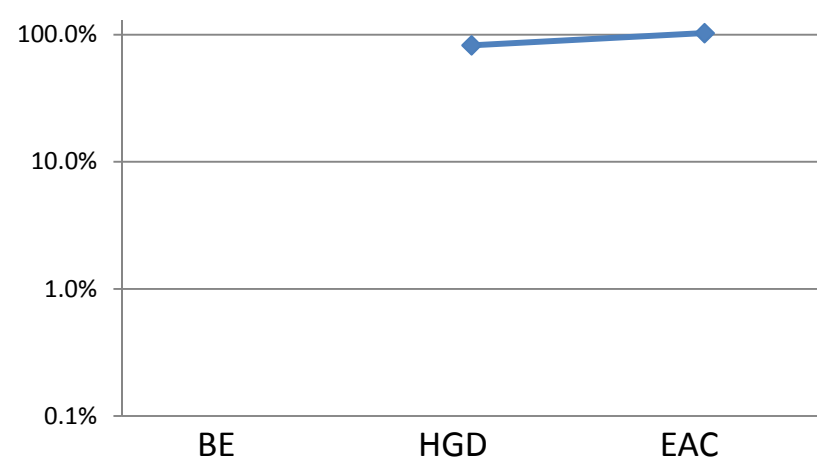
**Concurrent Patient 19**



**Concurrent Patient 15**



**Concurrent Patient 20**



Supplementary Figure 1. Percent Vimentin methylation in esophageal adenocarcinomas and matched concurrent pre-cancerous Barrett's esophagus lesions in individual patients. BE: Barrett's Esophagus; HGD: High Grade Dysplasia; EAC: Adenocarcinoma of the Esophagus.