

# Classification of Aberrant Crypt Foci and Microadenomas in Human Colon<sup>1</sup>

Luca Roncucci,<sup>2</sup> Alan Medline, and W. Robert Bruce<sup>3</sup>

Departments of Medical Biophysics and Nutritional Sciences, University of Toronto and The Ontario Cancer Institute, Toronto, Ontario, Canada M4X 1K9 [W. R. B.]; Department of Pathology, Northwestern General Hospital, Toronto, Ontario, Canada M6M 3Z4 [A. M.]; and Istituto di Patologia Medica, University of Modena, Via Del Pozzo 71, 41100 Modena, Italy [L. R.]

## Abstract

**Aberrant crypt foci (ACF) can be observed and quantified on the mucosal surface of formalin-fixed human colon resections after staining with methylene blue. To determine whether these ACF could be identified in fresh tissue, 10 colon resections were collected after surgery for colorectal cancer. Unfixed and fixed flat normal colonic mucosa from each colon were scored for ACF under a dissecting microscope after methylene blue staining. The number of ACF per cm<sup>2</sup> and the average number of crypts per foci correlated highly in unfixed and fixed mucosa ( $r = 0.93$  and  $0.78$ , respectively). A significantly higher frequency of lesions was found in left-sided compared to right-sided colon resections.**

**To determine whether the topographic features of the ACF gave an indication of the histological appearance, 68 specimens containing ACF or normal mucosa were examined histologically. The presence of slit-like lumen in the crypts of ACF on the mucosal surface correlated with the presence of dysplasia at histology, thus identifying microadenomas.**

**These two observations suggest that the topographic classification of ACF *in vivo* could be used to distinguish microadenomas, a putative precursor lesion of colon cancer.**

## Introduction

ACF,<sup>4</sup> similar to those seen in experimental animals exposed to colon carcinogens (1-2), have been identified and quantified on the mucosal surface of fixed human colon resections after methylene blue staining (3, 4). Methylene blue has also been used by Muto *et al.* (5) and Kuramoto *et al.* (6) *in vivo* to observe small flat and depressed adenomas during endoscopic examination. To

determine whether ACF could be similarly observed *in vivo*, we examined unfixed and fixed colonic mucosa obtained after surgery for colorectal cancer under a dissecting microscope and compared the frequency of the lesions that could be visualized in the two situations.

Many of the ACF in humans showed dysplasia at histological examination and were considered to be MA (3). To determine whether the shape of the lumens of the aberrant crypts was related to histological appearance, we also compared the luminal pattern of the aberrant crypts in the lesions observed with methylene blue with the grading of dysplasia of the same lesions examined in histological sections stained with hematoxylin and eosin.

We report here that ACF and MA can be easily identified and quantified on the unfixed mucosal surface of colon resections and that some topographic features of the abnormal crypts can be used to identify the presence of dysplasia.

## Materials and Methods

Colon resections were collected from a total of 10 patients receiving surgical treatment for colorectal cancer at the Northwestern General and North York General Hospitals of Toronto. Demographic and pathologic data for each patient are shown in Table 1 (Columns 1-4). The average age of the patients was  $70.3 \pm 16.6$  (SD) years. Each colon resection was opened, washed with isotonic solution, and examined within 1 h after the operation. The segment of the colon that was free of any grossly visible lesion and was not required for diagnostic purposes by the pathologists was cut longitudinally along the main axis. One-half of the colon segment was immediately examined, and the other half was placed between filter papers to reduce mucosal folding, fixed in 10% buffered formalin for at least 24 h, and examined at a later time. Flat mucosa of normal appearance was excised from both the unfixed and the fixed tissue. The area of each measured 15 to 70 cm<sup>2</sup>. The samples were dipped in a 0.1% solution of methylene blue in Krebs-Ringer buffer for 15-20 min, placed on a piece of glass with the mucosal surface up, and observed under a dissecting microscope at a magnification of  $\times 20-30$ . The light source was a MK II fiber optic light (Ehrenreich Photo Optical Industries, Garden City, NY). The number of ACF and the number of crypts in each aberrant crypt focus were recorded.

At the same time the pattern of the luminal outline in the abnormal crypts within the lesions was also recorded. Three different types of luminal patterns were classified as follows: a serrated luminal outline seen in round or elongated crypts; round dilated lumens observed in enlarged crypts; and slit-like lumens evident in

Received 4/8/91.

<sup>1</sup> Supported by grants from the Ministry of Health of Ontario and the National Cancer Institute of Canada.

<sup>2</sup> Supported by a grant from the National Research Council of Italy.

<sup>3</sup> To whom requests for reprints should be addressed, at Ontario Cancer Institute, 500 Sherbourne St., Toronto, Ontario, Canada M4X 1K9.

<sup>4</sup> The abbreviations used are: ACF, aberrant crypt foci; MA, microadenomas.

Table 1 Demographic, pathologic, and scoring data of the colorectal cancer patients examined for ACF with methylene blue staining on the mucosal surface

Patient	Sex	Age (yr)	Site	Area scored (cm <sup>2</sup> )	No. ACF	Mean no. crypts/ACF	No. ACF/cm <sup>2</sup>
1	F	85	CEC <sup>a</sup>	40.4	2	20.0	0.04
2	F	81	CEC	51.1	1	25.0	0.01
3	F	72	CEC	42.9	3	50.6	0.06
4	M	29	ASC	102.1	8	60.0	0.07
5	F	81	ASC	49.1	1	33.0	0.02
6	M	79	SIG	106.3	15	53.4	0.14
7	M	73	SIG	64.0	85	24.7	1.30
8	M	59	SIG	32.2	18	44.0	0.55
9	M	80	REC	136.8	41	88.6	0.29
10	M	64	REC	43.7	16	54.5	0.36

<sup>a</sup> CEC, cecum; ASC, ascending colon; SIG, sigmoid colon; REC, rectum.

enlarged and elongated crypts. Lesions from both fixed and unfixed tissue were photographed after removing the submucosa and muscularis propria. Examples of the luminal patterns are shown in Fig. 1.

**Histological Scoring.** Fifty-three 4 × 4-mm specimens containing ACF together with 15 similar specimens of normal mucosa were excised, coded, and processed for routine histological analysis. No cases of familial polyposis were included in the study. Four of ten cases had grossly visible incidental polyps with no apparent bearing on the number or appearance of the lesions seen with methylene blue staining. All excised foci and normals were derived from the 10 colon resections with each possessing a solitary cancer. Serial 5- $\mu$ m sections were cut parallel to the mucosal surface and stained with hematoxylin and eosin. To avoid the morphological variability frequently seen in the generative zone at the base of crypts, only the superficial portion of the crypts were included in the results (*i.e.*, superficial 20  $\mu$ m). The presence or absence of ACF and the grading of alterations were recorded by one pathologist. ACF in which the crypts had a serrated lumen and no dysplasia were considered hyperplastic lesions. Absence of dysplasia was defined as the presence of enlarged crypts with round dilated lumens and no nuclear atypia. ACF in which the crypts revealed loss of mucosal polarity (elliptical crypts with varying orientation of the lumens in the same lesion), increased size and number, elongation, and hyperchromatism of nuclei with focal or extensive stratification were classified as dysplastic. ACF with dysplasia were considered MA. Fig. 2 depicts examples of dysplasia observed on histology.

**Statistical Methods.** Comparison of the numbers of ACF/cm<sup>2</sup> between right-sided and left-sided colon resections was made using the Mann-Whitney test. A *P* value of less than 5% (*P* < 0.05) was considered significant. Pearson's correlation coefficients were calculated for the results of scoring for ACF on unfixed and fixed mucosa.  $\kappa$  statistic (7) was used to measure the agreement between the ACF observed from the mucosal surface and histological analysis of crypt alteration.

## Results

ACF were observed on the mucosal surface of both unfixed and fixed colonic mucosa as clusters of crypts that were darker and larger when compared with the normal surrounding crypts. The numbers of ACF/cm<sup>2</sup> in

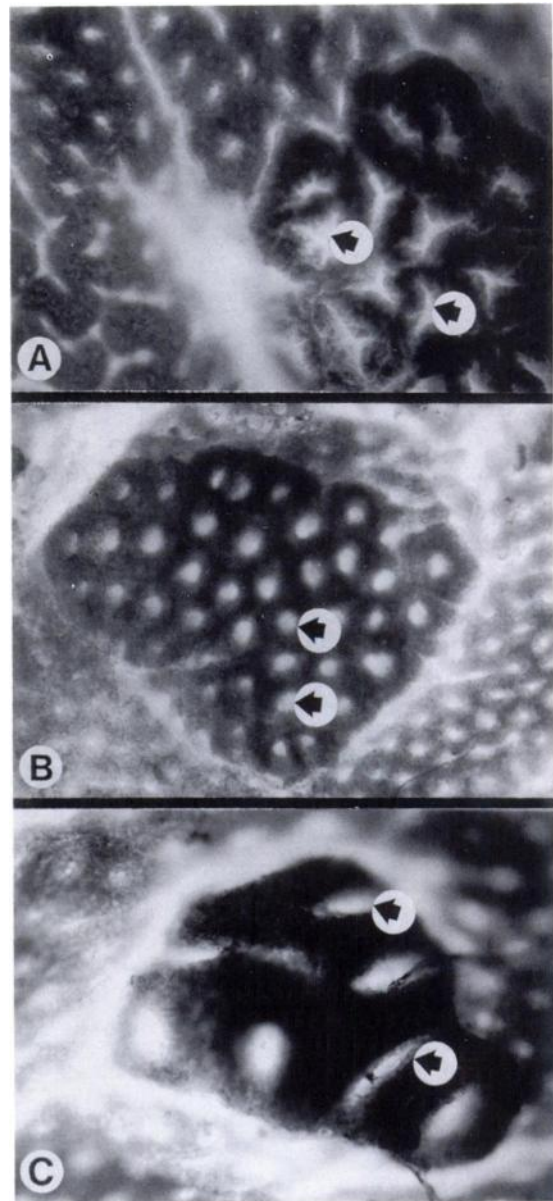


Fig. 1. Examples of the three luminal patterns observed in the ACF of the lesions examined with methylene blue using a dissecting microscope,  $\times 100$ . A, serrated lumens (arrows); B, round dilated lumens (arrows); C, elongated slit-like lumens (arrows).

unfixed and fixed colonic mucosa correlated highly as shown in Fig. 3 (correlation coefficient, *r* = 0.93). The numbers ranged from 0 to 1.07 in unfixed mucosa and from 0 to 1.54 in fixed mucosa. The average numbers of crypts/ACF were also comparable in unfixed and fixed tissue (*r* = 0.78), ranging from 25 to 94 in unfixed and from 20 to 87 in fixed mucosa (data not shown). In each colon collectively considered (unfixed + fixed mucosa) we found at least one ACF. Higher numbers and significantly higher frequencies of ACF were observed in left as compared to right colons (*P* < 0.05; Table 1).

At histological examination the 15 control specimens with no ACF on methylene blue staining were normal on



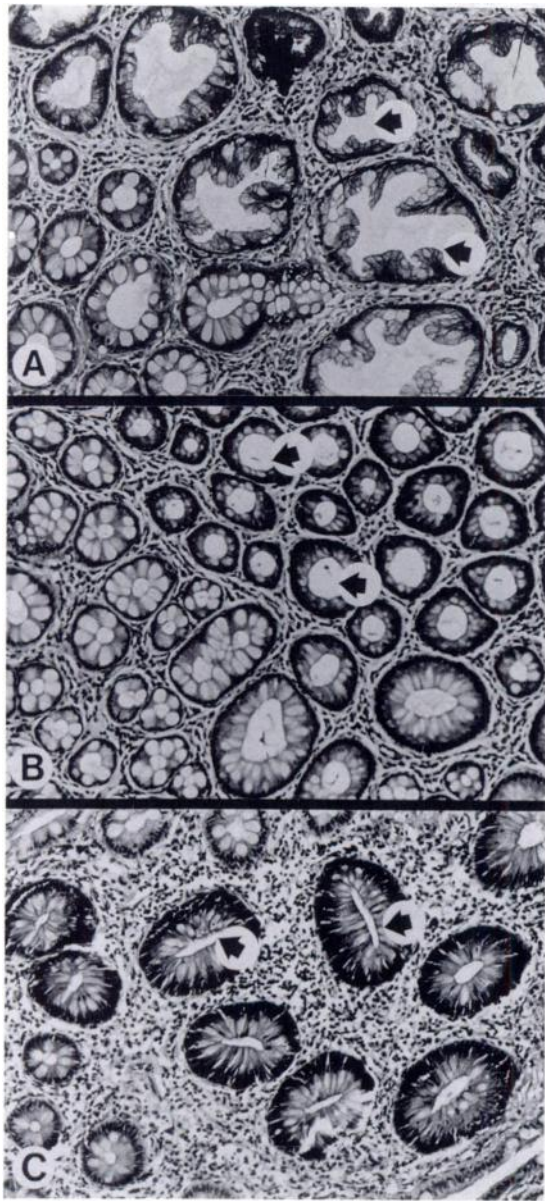


Fig. 2. Examples of the histological appearance of aberrant crypt foci. H & E,  $\times 200$ . A, hyperplastic epithelium with serrated lumens (arrows). No dysplasia is evident; B, dilation of crypt lumens with no dysplasia (arrows); C, dysplasia. Crypts exhibit slit-like lumens with varying orientation (arrows). Note the hyperchromatism and extensive stratification of the nuclei. Lesions with dysplasia are felt to represent microadenomas.

microscopic examination. The histological appearance of the remaining 53 specimens containing ACF is detailed in Table 2. Nine of the ten ACF with slit-like lumens were associated with dysplasia, while three of the remaining 43 ACF showed dysplasia. These numbers lead to a  $\kappa$  statistic of 0.77, which is highly significant ( $P < 0.001$ ) and is considered an indication of strong association (7). The association of the serrated luminal pattern with hyperplastic lesions on histology was less marked, with 7 of 14 cases showing the association. ACF with round lumens on methylene blue staining showed no dysplasia

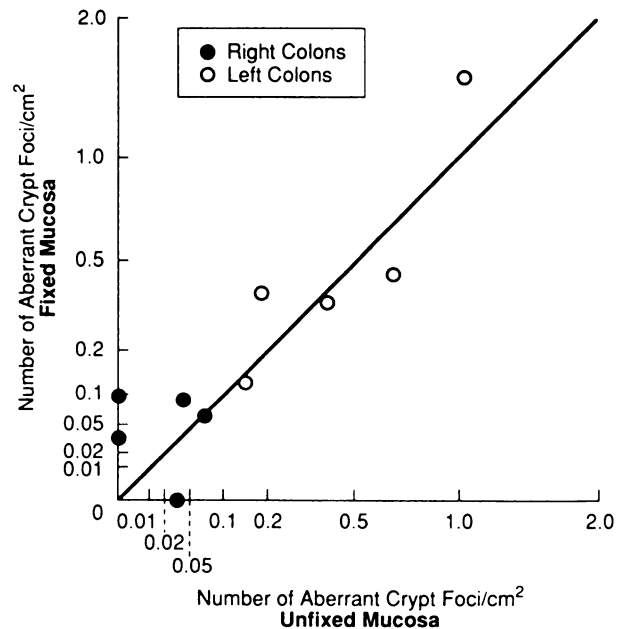


Fig. 3. Correlation of the number of ACF per  $\text{cm}^2$  between unfixed and fixed colonic mucosa in each colon examined.

or no apparent lesion in most specimens, but in three cases low grade dysplasia was observed.

### Discussion

The present study demonstrates that ACF can be identified on the mucosal surface of unfixed colons as easily as they can in the fixed resections. The frequency of ACF/ $\text{cm}^2$  and the average size of the foci in the mucosa of unfixed and fixed samples of the same colon resections correlated highly. Wide ranges of ACF per  $\text{cm}^2$  and of average number of crypts per ACF were found in the segments of colons examined, similar to those reported in previous studies (3, 4). The frequency of ACF in the segments of colon examined varied over 100-fold, from 0.01 to 1.30 ACF/ $\text{cm}^2$  (Table 1, Column 8). Left colons had the highest frequencies. The average size of the lesions ranged from 25 to 88 crypts/ACF (Table 1, Column 7).

ACF observed with methylene blue were associated with abnormal crypts on histological examination in most cases. The three luminal patterns of ACF observed from the mucosal surface with methylene blue staining were compared with the histological grading of dysplasia in Table 2. The slit-like luminal pattern was associated with the presence of dysplasia on histological examination identifying MA, although low-grade dysplasia was also observed in some ACF with round lumens. The neoplastic appearance of the dysplastic lesions strongly favors the use of a term such as microadenoma for these foci. The presence of hyperplastic epithelium was observed on histology only in ACF with serrated or round lumens.

A colonoscope with a suitable magnification attachment should be able to identify MA *in vivo*, just as flat adenomas have been observed previously using methylene blue staining during endoscopic examination (5). Using this approach it would now appear to be possible

Table 2 Comparison between the shape of lumen of the aberrant crypt foci at topographical analysis and the grading of dysplasia at histological examination

	Appearance of ACF from mucosal surface			Total
	Round	Serrated	Elongated	
No lesion apparent	6	1	0	7
Hyperplastic	1	7	0	8
Histology: nondysplastic	19	6*	1	26
Dysplasia	3	0	9	12
Total	29	14	10	53

\* On histology enlarged round lesions were seen.

to study the natural history of MA, the putative precursor lesions of colon cancer, and to examine the association of MA with presumed genetic and environmental risk factors.

### Acknowledgments

We are grateful to Drs. A. H. Qizilbash, J. Murray, R. Shaw, and A. Collins and to E. Pines from the North York General Hospital of Toronto for

providing the necessary material. Special thanks to Dr. S. Minkin for his advice on the statistical analysis of the data, to Dr. S. Rabinovich for valuable suggestions in reviewing the manuscript, to Janice Millard and Jill Fox for their excellent technical assistance, and to Jo-Ann Ciampini for the preparation of the manuscript.

### References

1. Bird, R. P. Observation and quantification of aberrant crypts in the murine colon treated with a colon carcinogen: preliminary findings. *Cancer Lett.*, 37: 147-151, 1987.
2. Bird, R. P., McLellan, E. A., and Bruce, W. R. Aberrant crypts, putative precancerous lesions, in the study of the role of diet in the aetiology of colon cancer. *Cancer Surv.*, 8: 189-200, 1989.
3. Roncucci, L., Stamp, D., Medline, A., et al. Identification and quantification of aberrant crypt foci and microadenomas in the human colon. *Hum. Pathol.*, 22: 287-294, 1991.
4. Pretlow, T. P., Barrow, B. J., Aston, W. S., O'Riordan, M. A., Jurcisek, J. A., and Stellato, T. A. Aberrant crypts: putative preneoplastic foci in human colonic mucosa. *Cancer Res.*, 51: 1564-1567, 1991.
5. Muto, T., Kamiya, J., Sawada, T., et al. Small "flat adenoma" of the large bowel with special reference to its clinicopathologic features. *Dis. Colon Rectum*, 28: 847-851, 1985.
6. Kuramoto, S., Ihara, O., Sakai, S., et al. Depressed adenoma in the large intestine: endoscopic features. *Dis. Colon Rectum*, 33: 108-112, 1990.
7. Fleiss, J. L. The measurement of interrater agreement. *In: Statistical Methods for Rates and Proportions*, Ed. 2, pp. 212-236. New York: J. Wiley, 1981.

# Cancer Epidemiology, Biomarkers & Prevention

## Classification of aberrant crypt foci and microadenomas in human colon.

L Roncucci, A Medline and W R Bruce

*Cancer Epidemiol Biomarkers Prev* 1991;1:57-60.

**Updated version** Access the most recent version of this article at:  
<http://cebp.aacrjournals.org/content/1/1/57>

**E-mail alerts** [Sign up to receive free email-alerts](#) related to this article or journal.

**Reprints and Subscriptions** To order reprints of this article or to subscribe to the journal, contact the AACR Publications Department at [pubs@aacr.org](mailto:pubs@aacr.org).

**Permissions** To request permission to re-use all or part of this article, use this link <http://cebp.aacrjournals.org/content/1/1/57>. Click on "Request Permissions" which will take you to the Copyright Clearance Center's (CCC) Rightslink site.