

Lewis Antigen Alterations in a Population at High Risk of Stomach Cancer¹

Julio Torrado, Martyn Plummer,² Jorge Vivas, Jone Garay, Gladys Lopez, Simon Peraza, Elsa Carillo, Walter Oliver, and Nubia Muñoz

Nuestra Señora de Aránzazu Hospital, University of the Basque Country, San Sebastián, Spain [J. T., J. G.]; International Agency for Research on Cancer, Lyon, France [M. P., N. M.]; and Cancer Control Center of the Tachira State, San Cristobal, Venezuela [J. V., G. L., S. P., E. C., W. O.]

Abstract

Anomalous Lewis^a antigen and sulfomucin expression are considered as markers of progression in precursor lesions of gastric cancer. Additionally, Lewis antigen and secretor phenotype have been related to *Helicobacter pylori* infection and gastric epithelial damage. The two objectives of this study were to correlate Lewis antigen alterations with histochemical changes and to explore the relationship between Lewis and secretor phenotypes and gastric epithelial damage related to *H. pylori* infection. The study subjects were selected from a chemoprevention trial in Tachira State, Venezuela, an area with a high risk of gastric cancer.

Anomalous Lewis^a antigen expression in Lewis (a–b+) phenotype individuals was closely related to the severity of the histological lesions, especially to dysplasia and type III intestinal metaplasia lesions. A weak relationship was observed between nonsecretor individuals and more advanced lesions of IM, but this association was not statistically significant. There was no relationship between secretor phenotype and *H. pylori* status, atrophy, regenerative activity, erosion, or ulcer.

Introduction

Blood group antigens (Lewis and ABH antigens) are carbohydrate structures originally identified on RBC by Landsteiner. However, these antigens are widely expressed in many tissues throughout the body, being especially abundant in the epithelial cells of gastric mucosa. The secretor status is defined by the presence of ABH antigens in body fluids and secretions like saliva, gastric juice, and milk.

Lewis (Lewis^a, Lewis^b) and ABH antigens are closely interrelated, and in mucosecretory epithelia they are produced from a common precursor (type 1 precursor) by the action of different genes. In the gastric foveolar cells, the expression of

Lewis and ABH antigens is fundamentally controlled by the action of the secretor and Lewis genes (Fig. 1). In people who have the secretor and Lewis genes, all of the precursor substance is transformed in H type 1 antigen, and they express Lewis^b and ABH antigens in the foveolar epithelium and in the gastric juice as well. People who do not have the secretor gene cannot produce Lewis^b or ABH antigens and, if they have the Lewis gene, all of the precursor is transformed into Lewis^a antigen. Finally, people who do not have the Lewis gene do not express Lewis^a or Lewis^b in gastric mucosa or gastric juice, and they express ABH antigens only if they have the secretor gene (1–3).

Blood group antigens appear to play an important role in cell recognition, differentiation, and growth regulation and during the process of malignant transformation these antigens undergo important alterations (4).

Lewis system abnormalities have been described in gastric carcinoma and precursor lesions. The anomalous expression of Lewis^a antigen in areas of IM³ of the stomach in Lewis (a–b+) individuals has been considered as a risk marker in the gastric precancerous process.

To explore the role of the alterations in the expression of Lewis antigens in the gastric precancerous process, we have studied histochemical and antigenic anomalies on gastric biopsies from a population from the Andean region in Venezuela with high risk for gastric cancer. We have correlated the Lewis and secretor phenotypes with histological lesions and with *Helicobacter pylori* status. The expression of anomalous Lewis^a antigen in relation to the type of IM was also investigated.

Materials and Methods

Subjects in this study were selected from a randomized double blind, placebo-controlled chemoprevention trial, currently being conducted in Tachira State, Venezuela, the aim of which is to assess the effect of antioxidant vitamins on progression of precancerous lesions of the stomach. The results presented here are a cross-sectional analysis of the subjects who had a histological diagnosis of IM at baseline. Although follow-up data are available, analysis of these data has been deferred until the randomization code is broken and the cohort of subjects receiving placebo can be identified.

The design of the chemoprevention trial has been described in detail elsewhere (5). Briefly, participants in the trial were recruited from the Gastric Cancer Control Program of Tachira State. Eligible subjects were permanent residents of Tachira between 35 and 69 years of age who, after double contrast X-ray, were selected to undergo gastroscopic examination. At entry into the trial, physical examination, blood collection, and gastroscopy were performed. Five biopsies for histological assessment were taken: one from the lesser curvature of the antrum, ~1 cm from the pylorus; one from the greater

Received 11/2/99; revised 3/8/00; accepted 4/13/00.

The costs of publication of this article were defrayed in part by the payment of page charges. This article must therefore be hereby marked *advertisement* in accordance with 18 U.S.C. Section 1734 solely to indicate this fact.

¹ This work was supported by Fondo de Investigacion Sanitaria y la Consejeria de Salud del Gobierno Vasco.

² To whom requests for reprints should be addressed, at IARC, 150 Cours Albert Thomas, F-69372 Lyon, France. Phone: (+33) 04 72 73 84 46; Fax: (+33) 04 72 73 85 75.

³ The abbreviation used is: IM, intestinal metaplasia.

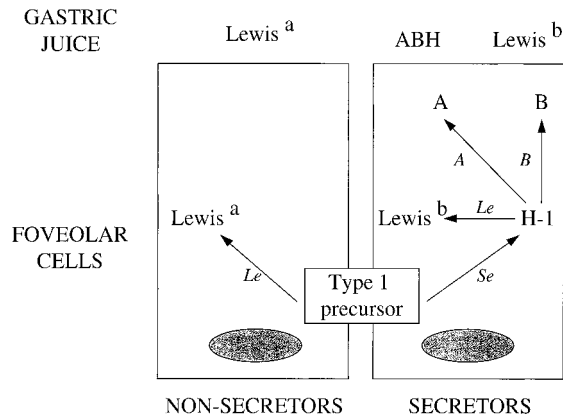


Fig. 1. Effect of Lewis and secretor genes on production of Lewis and ABH antigens in two foveolar cells.

curvature of the antrum, ~1 cm above the pylorus; one from a midportion of the lesser curvature of the antrum; one from the lesser curvature of the antrum immediately below the incisura; and one from the middle corpus, ~2 cm from the lesser curvature.

Gastric biopsies were fixed in buffered formalin and stained with H&E and Giemsa to detect *H. pylori*. The most severe lesion among all biopsies was considered for the global diagnosis and for the immunohistochemical studies. Those biopsies positive for IM were also stained with periodic acid-Schiff-Alcian blue (6) and high iron diamine-Alcian blue (7) to determine subtypes of IM that were classified according to the method of Filipe and Jass (8) as follows. Type I is characterized by the presence of mature goblet and absorptive cells with a well-defined brush border. Goblet cells secrete sialomucins. In type II, there is mild architectural distortion, crypts are lined by goblet cells, absorptive cells are few or absent, and columnar mucous cells are present containing a mixture of neutral and acid sialomucins. The goblet cells secrete sialomucins or occasionally sulfomucins, or both. In type III, the overall architecture is more disorganized than in type II. Columnar cells secrete sulfomucins, and goblet cells contain sialo- or sulfomucins.

Lewis and secretor phenotypes were determined by immunohistochemistry in nonmetaplastic areas of gastric mucosa, as previously reported (9). Anti-A (A581, Dako; working dilution, 1:40), anti-B (A582, Dako; working dilution, 1:40), and anti-H type 2 (A583, Dako; working dilution, 1:40) were used to determine the secretor phenotype. The presence of ABH antigens in the foveolar epithelium defined the secretor phenotype; a negative detection identified the nonsecretor phenotype. Anti-Lewis^a (7LE, Biogenex; working dilution, 1:250) and anti-Lewis^b (2.25LE, Biogenex; working dilution, 1:250) were used to determine the Lewis phenotype. A diffuse positive reaction for anti-Lewis^a and anti-Lewis^b monoclonal antibodies defined the Lewis (a+b-) and the Lewis (a-b+) phenotypes, respectively; absence of both positive reactions defined the Lewis (a-b-) phenotype.

Sections for immunohistochemistry were deparaffinized, rehydrated, and successively incubated with: 8% (v/v) hydrogen peroxide in distilled water for 10 min at room temperature; primary antibodies (working dilution prepared with Primary Antibody Diluent from Biomedica, Foster City, CA) for 30 min at 37°C; biotinylated rabbit antimouse immunoglobulin (Biomedica) for 5 min at 37°C; alkaline phosphatase-labeled streptavidin (Ultra Probe; Biomedica) for 10 min at 37°C; and a freshly prepared solution of 100 mM Tris base, 200 mM NaCl, 5 mM MgCl₂, 0.35% HCl, and

0.05% Tween 20, pH 9.0, with naphthol AS-MX phosphatase/Fast Red TR chromogen (Biomedica), for 15 min at room temperature. Sections were faintly counterstained with Lillie's hematoxylin and mounted with Crystal-Mount (Biomedica). Positive and negative controls were stained with every batch of samples. In the deparaffinized tissues used, the specificity of primary antibodies is restricted to the mucin glycoprotein fractions of these antigenic determinants and was previously determined. Working dilutions were established by serial titration.

We investigated the aberrant expression of Lewis^a antigen in all Lewis (a-b+) patients. This alteration was categorized in three patterns (see Ref. (9) for full description and illustrations): pattern I, anomalous antigen expressed only in some goblet cells; pattern II, anomalous antigen expressed in goblet cells and weakly in columnar cells; pattern III, anomalous antigen strongly positive in both goblet and columnar cells.

For all variables measured at the level of the individual biopsy, except for *H. pylori* status, an overall score was calculated for each subject by taking the most severe of the available biopsy scores, and this overall score was used in the tabulations and tests. For *H. pylori* status, the overall prevalence in all five biopsies was used for the tabulation, and the difference between secretors and nonsecretors was tested by Wilcoxon rank sum test, with the use of the average of the five biopsy scores (rated 1-4 for negative, difficult to find, easy to find, and abundant, respectively).

Two statistical tests were used to examine the relationships between cross-tabulated variables. The χ^2 test was used as a global test for any relationship, and a trend test (10) was used to look for a smoothly increasing trend if one of the variables was ordinal.

The data on abnormal Lewis^a secretion and histological diagnosis were examined by applying a log linear Poisson model to the tabulated data. When controlling for age and other confounders, a separate multiple logistic regression model was used for outcomes of IM-II, IM-III, and dysplasia, with IM-I as a common baseline.

Results

Gastric biopsies taken at baseline were studied from 564 subjects with a global diagnosis of IM or dysplasia. The most severe lesion among all biopsies was considered as the global diagnosis. The subjects ranged in age from 34 to 71 (mean, 51), and 269 were men and 295 women. The secretor status was determined in only 552 patients.

The prevalence of the different histological lesions was 58% for type I IM, 12% for type II, 13% for type III IM, and 17% for dysplasia. In dysplastic cases, 81% showed mild, 17% showed moderate, and 2% showed severe dysplasia.

Table 1 shows the Lewis and secretor phenotype distribution by sex. There is no significant difference in the distribution of either phenotype by sex. A high proportion (93%) of Lewis (a-b-) phenotype subjects were secretors. The prevalence of Lewis (a+b-) and nonsecretor individuals was lower than that of the European population, a fact observed in other Andean populations (9).

Secretor Status and *H. pylori* Infection. Table 2 shows the distribution of histological diagnosis by secretor status. There is an excess of secretors in the group of subjects with IM-I, but overall there is no significant difference in the distribution of the histological diagnoses between secretors and nonsecretors ($P = 0.16$; test for trend, $P = 0.10$).

Table 3 shows the relationship between secretor status and *H. pylori* infection, rated on a four point scale (negative, difficult to find, easy to find, abundant). *H. pylori* infection is very common in this population: 94% of the participants in the chemoprevention trial are infected. There is no significant difference

Table 1 Distribution of Lewis phenotype and secretor status by sex

Sex	Lewis phenotype			Secretor status	
	Le(a+b-)	Le(a-b+)	Le(a-b-)	Secretor	Nonsecretor
Male	31 (12) ^a	187 (71)	44 (17)	227 (87)	35 (13)
Female	29 (10)	217 (75)	44 (15)	259 (89)	31 (11)
Total	60 (11)	404 (73)	88 (16)	486 (88)	66 (12)

^a Numbers in parentheses, percentage.

Table 2 Distribution of histological diagnosis by secretor status

Secretor status	Histological diagnosis				Total
	IM-I	IM-II	IM-III	Dysplasia	
Secretor	289 (59) ^a	56 (12)	63 (13)	78 (16)	486
Nonsecretor	30 (45)	12 (18)	11 (17)	13 (20)	66
Total	319 (58)	68 (12)	74 (13)	91 (17)	552

^a Numbers in parentheses, percentage.

Table 3 Extent of *H. pylori* infection (overall prevalence in subjects with complete biopsy information) by secretor status

Secretor status	<i>H. pylori</i> (%)			
	Negative	Difficult to find	Easy to find	Abundant
Secretor (n = 452)	17	25	50	8
Nonsecretor (n = 62)	23	26	43	8

between secretors and nonsecretors in degree of *H. pylori* infection ($P = 0.18$). Secretor status was also examined in relation to three markers of cellular or mucosal damage, atrophy, regenerative activity, and erosion or ulcer, which were rated on a four point scale for each biopsy (negative, light, moderate, and severe for atrophy and regenerative activity and negative, superficial, mucosal penetration, and submucosal penetration for erosion or ulcer). No relationship was found with any of these markers (tables not shown; $P = 0.77$ for atrophy, $P = 0.42$ for regenerative activity, and $P = 0.57$ for erosion or ulcer. Trend test results, $P = 0.32$, $P = 0.94$, $P = 1.00$, respectively).

In summary, there is weak evidence of a correlation between secretor status and severity of histological diagnosis, but this could not be related to *H. pylori* infection.

Abnormal Expression of Lewis^a in Lewis (a-b+) Individuals, by Type of IM. Table 4 shows the relationship between abnormal expression of Lewis^a antigen and histological diagnosis in Lewis (a-b+) individuals. This relationship is shown in Fig. 2. With IM type I as a baseline, there is a clear increasing risk of dysplasia, IM type III, and IM type II with an increasing degree of abnormal expression of Lewis^a. The trends are all strongly significant ($P < 0.001$ for dysplasia, $P < 0.001$ for IM-III, and $P = 0.002$ for IM-II). The trend for IM-III is stronger than for IM-II ($P = 0.02$), but the trend for dysplasia is weaker than for IM-III.

These results were unchanged after controlling for the confounding effect of age, sex, years of education (as a marker of socioeconomic status), and smoking status, which have been previously identified as risk factors for advanced precancerous lesions in this population.

Discussion

The intestinal or epidemic type of gastric cancer is considered the end result of a multistep process in which multiple factors

are involved. *H. pylori* infection, dietary factors, nitroso compounds, oxidative damage, and lack of antioxidant vitamins produce a series of changes in the gastric epithelium which include progressive grades of atrophy, IM, and dysplasia and, finally, a malignant transformation (11). In this dynamic process, progressive alterations in the mucin components and the expression of anomalous antigens may be also observed.

Alterations in the expression of blood group antigens have been extensively described in gastric cancer (12–15). It has been proposed that these anomalies are produced by blockages in the normal synthesis of these antigens, resulting in loss of some of these structures and the appearance of aberrant antigens. The anomalous expression of Lewis^a antigen in lesions of gastric intestinal IM and dysplasia from Lewis (a-b+) individuals has been previously reported. In our experience, this abnormality has not been observed in the earlier lesions of chronic gastritis and gastric atrophy or in areas of normal gastric mucosa. Previous studies have demonstrated that the simultaneous expression of anomalous Lewis^a antigen and sulfomucins indicates a greater risk of preneoplastic progression (9, 16).

Our results show an increasing frequency in the prevalence and grade of severity of the anomalous Lewis^a antigen expression correlated to the severity of the histological changes and to the severity of the histochemical alterations (sialo- and sulfomucin expression). Thus, the most severe pattern of anomalous Lewis^a antigen expression (pattern III) was more prevalent in dysplastic cases than in type II or type III intestinal metaplasia.

The role of *H. pylori* as the most important etiopathogenic factor in chronic gastritis is well documented. However, its direct involvement in more advanced lesions (gastric atrophy, IM, dysplasia, and cancer) is poorly understood. Recently, the Lewis^b and H antigens have been described as the receptors responsible for the attachment of *H. pylori* to the gastric mucosa (17). The cytoplasm of the foveolar cells and the gastric mucus are very rich in these antigens, and this fact can explain the especial tropism of this bacterium for the gastric mucosa.

We think that in secretor individuals, the abundant presence of Lewis^b and H antigens in the gastric mucus acts as a protective mechanism that traps bacteria and prevents their attachment to the gastric epithelium. This protective mechanism has been proposed as an adaptive response to infective microorganisms by Slomiany (18). In the present study, there is no relation-

Table 4 Histological diagnosis by degree of abnormal Lewis^a expression in Lewis (a-b+) subjects

Lewis alteration	Histological diagnosis				Total
	IM-I	IM-II	IM-III	Dysplasia	
Negative	97 (73) ^a	13 (10)	6 (5)	17 (13)	133
Pattern I	77 (70)	14 (13)	7 (6)	12 (11)	110
Pattern II	31 (53)	8 (14)	8 (14)	12 (20)	59
Pattern III	32 (33)	16 (16)	22 (22)	28 (29)	98
Total	237	51	43	69	400

^a Numbers in parentheses, percentage.

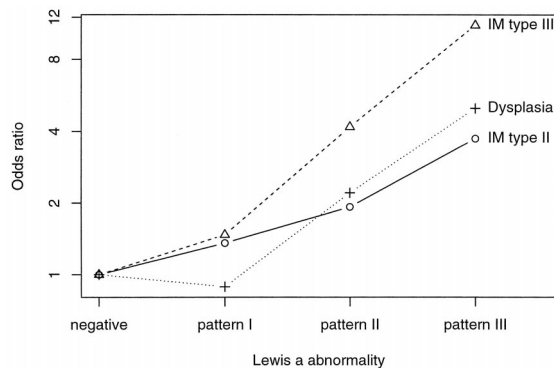


Fig. 2. Odds ratios of IM-II, IM-III, and dysplasia, using IM-I as baseline, by pattern of abnormal Lewis^a expression in Lewis (a-b+) subjects.

ship between *H. pylori* infection and secretor phenotype. This is not necessarily inconsistent with the theory that *H. pylori* is trapped in the gastric mucosa in secretor individuals. When rating the degree of *H. pylori* infection, it was not possible to distinguish between bacteria attached to cells and bacteria in mucus.

Previously, we have observed a lower epithelial damage, grade of atrophy, and a lower prevalence of sulfomucin expression in secretor individuals than in nonsecretors. In this study, there was no relationship between secretor status and atrophy, regenerative activity or erosion or ulcer.

A strong relationship between the expression of sulfomucins and nonsecretor status has been described in precursor lesions of gastric cancer (19) and also in Barrett's esophagus and Barrett's adenocarcinoma (20). In the present study, there is a tendency for nonsecretors to have more type III IM and dysplasia than secretors but, possibly due to the small number of nonsecretor individuals, the difference was not significant.

In summary, our results indicate that at the same time as the morphological changes that occur during the process of gastric carcinogenesis, another series of events occurs. Thus, the anomalous appearance of Lewis^a and sulfomucins in areas of intestinal metaplasia appear to behave as immunohistological indicators of a greater severity of morphological lesions. Further follow-up studies are required to clarify the role of predictive markers of risk in precursor lesions of gastric cancer.

Acknowledgments

We thank Olga Andrade, Denis Castro, Victor Sanchez, and Elsa Cano for their work as histotechnicians; and Gloria Moreno, Angel Chacon, and Jasmin Rangel for their work as endoscopists on this study.

References

1. Mollicone, R., Bara, J., Le Pendu, J., and Oriol, R. Immunohistologic pattern of type 1 (Le a, Le b) and type 2 (X, Y, H) blood group-related antigens in the human pyloric and duodenal mucosae. *Lab. Invest.*, 53: 219-227, 1985.

2. Mollicone, R., Le Pendu, J., Bara, J., and Oriol, R. Heterogeneity of the ABH antigenic determinants expressed in human pyloric and duodenal mucosae. *Glycoconj. J.*, 3: 187-202, 1986.

3. Torrado, J., Blasco, E., Cosme, A., Gutierrez-Hoyos, A., Arenas, J. I., and Cuadrado, E. Immunohistologic reactions of 20 monoclonal antibodies against non-A, non-B glycoconjugates with normal mucosae of the human gut. *Rev. Fr. Transfus. Immuno-hematol.*, 30: 693-698, 1987.

4. Coon, J. S., and Weinstein, R. S. Blood group-related antigens as markers of malignant potential and heterogeneity in human carcinomas. *Hum. Pathol.*, 17: 1089-1106, 1986.

5. Muñoz, N., Vivas, J., Buiatti, E., Kato, I., and Oliver, W. Chemoprevention trial on precancerous lesions of the stomach in Venezuela: summary of study design and baseline data. *In: B. W. Stewart, D. McGregor and P. Kleihues (eds.) Principles of Chemoprevention*, pp. 125-133. IARC Scientific Publ. No. 139. Lyon: IARC, 1996.

6. Luna, L. G. PAS-Alcian blue method for mucosubstances, pH 2.5. *In: L. G. Luna (ed.), Manual of Histologic Staining Methods of the Armed Forces Institute of Pathology*, Ed. 3, pp. 168-169. New York: McGraw Hill Book Co., 1968.

7. Spicer, S. S. Diamine methods for differentiating mucosubstances histochemically. *J. Histochem. Cytochem.*, 13: 211-234, 1965.

8. Filipe, M. I., and Jass, J. R. Intestinal metaplasia subtypes and cancer risk. *In: M. I. Filipe and J. R. Jass (eds.), Gastric Carcinoma*, pp. 97-115. Edinburgh: Churchill Livingstone, 1986.

9. Torrado, J., Correa, P., Ruiz, B., Bernardi, P., Zavala, D., and Bara, J. Lewis antigen alterations in gastric cancer precursors. *Gastroenterology*, 102: 424-430, 1992.

10. Breslow, N. E., and Day, N. E., *Statistical Methods in Cancer Research*. Vol. 1, pp. 147-148. IARC Scientific Publ. No. 32. Lyon: IARC, 1980.

11. Correa, P. Human gastric carcinogenesis: a multistep and multifactorial process: First American Cancer Society Award Lecture on Cancer Epidemiology and Prevention. *Cancer Res.*, 52: 6735-6740, 1992.

12. Picard, J., Edward, D. W., and Feizi, T. Changes in the expression of the blood group A, B, H, Lewis a and Lewis b antigens and the blood group precursor associated I (MA) antigen in glycoprotein-rich extracts of gastric carcinomas. *J. Clin. Lab. Immunol.*, 1: 119-128, 1978.

13. Sakamoto, J., Watanabe, T., Tokumaru, T., Tagaki, H., Nakazato, H., and Lloyd, K. O. Expression of Lewis a, Lewis b, Lewis X, Lewis Y, sialyl-Lewis a and sialyl-Lewis X blood group antigens in human gastric carcinoma and in normal gastric tissue. *Cancer Res.*, 49: 745-752, 1989.

14. Torrado, J., Blasco, E., Cosme, A., Ariel Gutierrez-Hoyos, A., and Arenas, J. I. Expression of type 1 and type 2 blood group-related antigens in normal and neoplastic gastric mucosa. *Am. J. Clin. Pathol.*, 91: 249-254, 1989.

15. Torrado, J., Blasco, E., Gutierrez-Hoyos, A., Cosme, A., Lojendio, M., and Arenas, J. I. Lewis system alterations in gastric carcinogenesis. *Cancer (Phila.)*, 66: 1769-1774, 1990.

16. Torrado, J., Correa, P., Ruiz, B., Zavala, D., and Bara, J. Prospective study of Lewis antigen alterations in the gastric precancerous process. *Cancer Epidemiol. Biomarkers Prev.*, 1: 199-205, 1992.

17. Borén, T., Falk, P., Roth, K. A., Larson, G., and Normark, S. Attachment of *Helicobacter pylori* to human gastric epithelium mediated by blood group antigens. *Science (Washington DC)*, 262: 1892-1895, 1993.

18. Slomiany, B. L., Murty, V. L., Piotrowski, J., and Slomiany, A. Gastroprotective agents in mucosal defense against *Helicobacter pylori*. *Gen. Pharmacol.*, 25: 833-841, 1994.

19. Torrado, J., Ruiz, B., Garay, J., Cosme, A., Arenas, J. I., Bravo, J. C., Fonham, E., and Correa, P. Lewis, secretor and ABO phenotypes and sulfomucin expression in gastric intestinal metaplasia. *Cancer Epidemiol. Biomarkers Prev.*, 6: 287-289, 1997.

20. Torrado, J., Ruiz, B., Garay, J., Asenjo, J. L., Tovar, J. A., Cosme, A., and Correa, P. Blood-group phenotypes, sulfomucins and *Helicobacter pylori* in Barrett's esophagus. *Am. J. Surg. Pathol.*, 21: 1023-1029, 1997.